

## CASE REPORT: MEDIASTITIS SECONDARY TO DEEP NECK ABSCESS, SHOULD STERNOTOMY BE DONE?

Muhammad Farhan Noor<sup>1</sup>, Michael Lekatompessy<sup>1,2\*</sup>, Maulidia Ayudika Dandanah<sup>1,3</sup>

<sup>1</sup>Faculty of Medicine, Pelita Harapan University, Indonesia; <sup>2</sup>Department of Otorhinolaryngology-Siloam Hospitals Lippo Village, Indonesia; <sup>3</sup> Department of Cardiothoracic Surgery-Siloam Hospitals Lippo Village, Indonesia

pISSN: 2828-4070

<https://doi.org/10.69951/proceedingsbookoficeonimeri.v7i-191>

Proceedings ICE on IMERI. 2023.

Received: October 16th, 2023

Accepted: November 04th, 2023

Published online: December 14, 2023

### Corresponding Author

Name : Michael Lekatompessy  
Email : michael.lekatompessy@uph.edu  
Mailing address : Department of Otorhinolaryngology, Faculty of Medicine, Pelita Harapan University, Boulevard Jendral Sudirman street, Karawaci, Tangerang, Indonesia 15811  
Telephone : +6281389867346  
Fax :-  
ORCID ID :-

### Abstract

A deep neck abscess is a treatable infection in the deep cervical space. The condition may have life-threatening complications. A complication that can happen secondary to the abscess is mediastinitis, and treating a patient with such a complication could be challenging. To emphasize that treatment by exploration of the abscess and insertion of a mediastinal drain could be an alternative therapy compared to sternotomy for mediastinitis secondary to deep neck abscess. A 39-year-old male came to the ER with a chief complaint of swollen and neck tenderness for the past five days, along with difficulty swallowing and chest pain. Radiographic examinations showed a retropharyngeal abscess with a widening mediastinum. The patient underwent surgery to drain the abscess. Cervical and mediastinal drains were inserted, and the patient was transported to the Intensive Care Unit for observation. The patient was extubated after three days, and both drains were removed on the fifth day. Deep neck abscess is still common in Indonesia, and mediastinitis is a complication of deep neck infections. A surgical approach is necessary when mediastinitis occurs as it is considered a medical emergency. Not all ICU units in Indonesia can provide or manage open sternotomy patients. Identifying complications, early detection, and treatment is crucial in determining the patient's prognosis.

### Keywords

Deep neck abscess, mediastinitis, mediastinal drain

### Introduction

A deep neck abscess is a treatable infection in the deep cervical space.<sup>1</sup> This infection is rapidly progressing and may have life-threatening complications. One complication that may happen secondary to the abscess is mediastinitis, and treating a patient with such complication could be challenging.<sup>2,3</sup> From the neck to the mediastinum; there are three potential routes of spread<sup>4,5</sup>: the pre-tracheal route to the anterior mediastinum, the lateral route through to the parapharyngeal to the middle mediastinum, and the retropharyngeal route to the posterior mediastinum. We present a case report of a patient with mediastinitis secondary to a deep neck abscess. We emphasized treatment by surgical abscess drainage, followed by cervical and mediastinal drain insertion.

### Case Report

A 39-year-old male came to the ER with a chief complaint of a swollen neck for the past five days, along with complaints of difficulty swallowing and chest pain. The patient complained of pain on the left part of the neck, which radiated into the gum and left ear. On physical examination, vital signs were within normal limits. Examination of the neck showed a tender mass located on the left mandible 4x5 cm in size. The examination also revealed crepitus extending to the sternal notch. Laboratory results were within normal limits. Cervical and chest x-rays showed widening of the mediastinum (Fig. 1) and signs of retropharyngeal abscess. CT scan showed gas formation extending from the left submandibular space, retropharynx, left paracarotid and visceral space, trachea, and inferior esophagus, reaching the bilateral superior mediastinum, which showed widening of the mediastinum. Mediastinitis should always be suspected when a wide mediastinum is found in cases of deep neck infections. The patient was then admitted to the operating room and underwent surgery for exploration and drainage of the abscess. The incision was done three centimeters below the left mandible. Around 150 milliliters of pus were identified. Exploration of the abscess revealed that the abscess reached past the sternum. A cardiothoracic surgeon continued the surgery. Cervical and mediastinal drains were inserted, and the patient was transported to the ICU for observation. On the third day after surgery, the patient was alert and extubated with only little complaints of sore throat. The patient was then transferred to the inpatient room. Both drains were removed on the fifth day after surgery, and the patient was discharged.

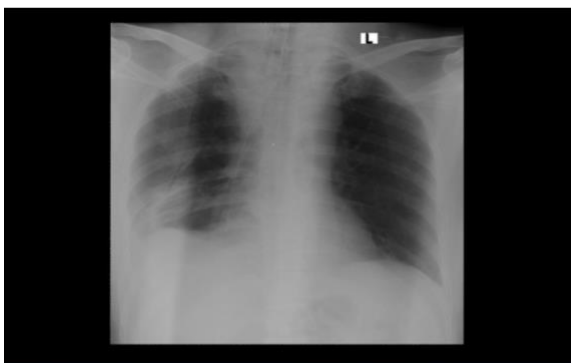


Figure 1. Chest X-ray showed widening of the mediastinum

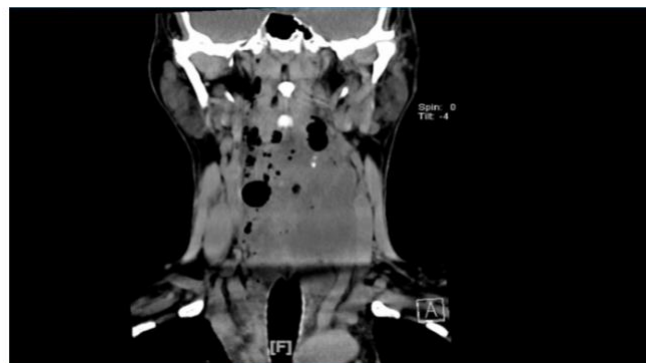


Figure 2. CT-Scan of the neck showed deep neck abscess

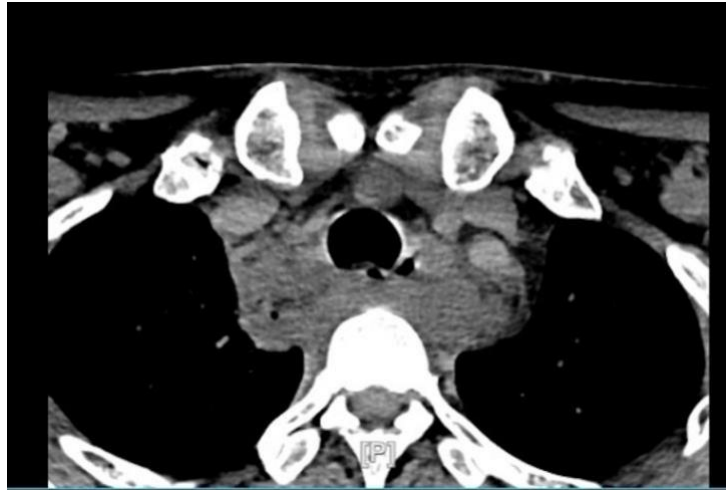


Figure 3. CT scan of the Mediastinum showed air fluid

## Discussion

This case described a 39-year-old male with mediastinitis secondary to deep neck infections. Surgical drainage with a transcervical approach is the definitive treatment for this case. Another incision was made above the sternum to drain the abscess. After draining the abscess, mediastinal debridement was done, and a mediastinal drain was inserted. In severe cases that cause complications, such as pleural effusion, a sternotomy may be performed to maximize mediastinal cleansing. In this case, sternotomy was not necessary, and treatment was exploration and drainage of the abscess with cervical and mediastinal drain insertion. An incision was made anterior to the sternocleidomastoid muscle, and finger dissection along the tracheoesophageal groove was done to reach the mediastinum. The neck and mediastinum was irrigated using betadine solution before the negative suction drain was inserted.

A study conducted at the Dr. Soetomo General Hospital in 2019 found that mediastinitis occurred in 18.18% of deep neck abscess cases, where most abscesses, around 31.7%, developed in the submandibular region.<sup>6</sup> In another study in the same hospital, it was found that mediastinitis originating from head and neck infections was the second most common complication, comprising 44.64% of cases.<sup>6</sup>

## Conclusion

Deep neck abscess is still common in Indonesia, where the most common source of infection is odontogenic, followed by head and neck infections. Mediastinitis is one of the most common complications following deep neck infections. A surgical approach is necessary when mediastinitis occurs, as it is considered a medical emergency. Aggressive debridement with mediastinum drainage should be done whenever mediastinitis is identified. Sternotomy may be done in large mediastinitis cases. Not all ICU units in Indonesia can provide or manage sternotomy patients. Identifying such complications, early detection, and treatment is crucial for the patient's prognosis.

## Competing Interests

The authors declare that they have no conflicts of interest.

## References

1. Almuqamam M, Gonzalez FJ, Kondamudi NP. Deep Neck Infections. [Updated 2022 Aug 14]. In: StatPearls [Internet]. Treasure Island (FL): StatPearls Publishing; 2023 Jan-. Available from: <https://www.ncbi.nlm.nih.gov/books/NBK513262>
2. Panda NK, Mann SB, Sharma SC. Mediastinitis following Deep neck infections : A therapeutic challenge. *Indian J Otolaryngol Head Neck Surg.* 2000;52(4):391–5. doi:10.1007/bf02991489
3. Gehrke, T., Scherzad, A., Hagen, R. et al. Deep neck infections with and without mediastinal involvement: treatment and outcome in 218 patients. *Eur Arch Otorhinolaryngol.* 2022;279:1585–1592. doi:10.1007/s00405-021-06945-9
4. Lugo-Machado J., Pérez M., Quintana Ó., Márquez F., Pinelli R., Lizárraga C., Alvarado A.. Descending mediastinitis secondary to deep neck abscess in a healthy patient: Case report. *Rom J Rhinol.* 3921;11(43): 130-133. doi:10.2478/rjr-2021-0022
5. Li RM, Kiemeny M. Infections of the neck. *Emerg Med Clin N Am.* 2019;37(1):95–107. doi:10.1016/j.emc.2018.09.003
6. Jiwangga D. Clinical characteristic and management of descending necrotizing mediastinitis: A retrospective study, dr. Soetomo Hospital, Surabaya. *J Vis Surg.* 2018;4:246–246. doi:10.21037/jovs.2018.12.01