

## PLATELET RICH PLASMA INJECTION FOR TREATMENT OF NEUROPATHY AFTER HERNIA REPAIR

Aida Rosita Tantri<sup>1</sup>, Yoseph Rohedi Asmara<sup>2</sup>, Lawrence Kwan<sup>1\*</sup>

<sup>1</sup>Department of Anesthesiology and Intensive Care, Faculty of Medicine, Universitas Indonesia, Dr. Cipto Mangunkusumo Hospital, Jakarta, Indonesia; <sup>2</sup>Department of Anesthesiology and Intensive Care, Tarakan General Hospital, Jakarta, Indonesia

pISSN: 2828-4070

<https://doi.org/10.69951/proceedingsbookoficeonimeri.v7i-.192>

Proceedings ICE on IMERI. 2023.

Received: October 16th, 2023

Accepted: November 04th, 2023

Published online: December 14, 2023

### Corresponding Author

Name : Lawrence Kwan  
Email : lawrence@ui.ac.id  
Mailing address : Department of Anesthesiology and Intensive Care, Faculty of Medicine, Universitas Indonesia, Dr. Cipto Mangunkusumo Hospital, Jakarta, Indonesia  
Telephone : +6281382121085  
Fax : -  
ORCID ID : -

### Abstract

A young male patient developed persistent severe right-sided groin and scrotal pain following hernia repair. After two months of failed conservative therapy, he was referred to the pain clinic. Genitofemoral Neuralgia was suspected because the area of pain corresponds to the innervation area of the Genitofemoral nerve. For diagnostic and therapeutic purposes, it was injected with local anesthetic and steroid using ultrasound guidance. The initial injection led to pain relief for one month. There are some choices for treating neuralgia after a confirmatory diagnostic block, such as neurolysis, pulsed radiofrequency, or surgical neurectomy. We chose Platelet Rich Plasma (PRP) injection because it has the potential for nerve regeneration and is less invasive. Ultrasound allows for controlled administration and greatly enhances the technical ability to perform precise localization and injection. The patient, in this case, has more than 50% pain reduction after PRP therapy. He no longer needs medication and can return to normal daily activities. This case report illustrates the first presentation of managing post-herniorrhaphy neuropathy using Platelet Rich Plasma.

### Keywords

CPSP, PRP, neuropathy, herniorrhaphy, chronic pain, neuralgia, nerve regeneration

### Introduction

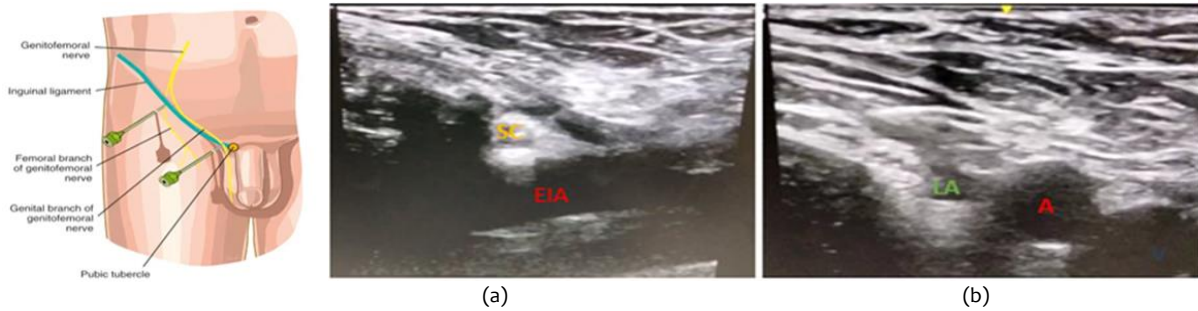
Chronic inguinal pain after hernia repair is a common and feared complication. The reported rate ranges from 10% to 63%; some are moderate-to-severe pain influencing daily activities.<sup>1</sup> One of the causes is nerve injury during surgery. Treatment for nerve-injury

related pain varies. Interventional techniques such as neurolysis to surgical neurectomy are generally performed after a confirmatory diagnostic block. However, these options are invasive.<sup>3</sup> On the other hand, Platelet Rich Plasma (PRP) is beneficial for nerve regeneration and simpler. We report a case of post-herniorrhaphy genitofemoral neuralgia, which improved with PRP therapy. Chronic inguinal pain after hernia repair is a common and feared complication. The rate reported range from 10%–63%, some are moderate-to-severe pain influencing daily activities<sup>1</sup>. One of the causes is nerve injury during surgery. Treatment varies. Interventional techniques such as neurolysis to surgical neurectomy are generally performed after a confirmatory diagnostic block, however, these are invasive<sup>3</sup>. On the other hand, Platelet Rich Plasma (PRP) is beneficial for nerve regeneration, yet more simple. We report a case of post-herniorrhaphy genitofemoral neuralgia which improved with PRP therapy.

### Case Report

A 32-year-old male patient was referred to the pain clinic because of pain in his right groin and scrotal area after having open hernia repair two months earlier. He has been given methylprednisolone, gabapentin, and mecobalamin with only temporary relief. Pain and tingling were described in the area corresponding to the innervation of the Genitofemoral nerve. The pain was felt throughout the day and greater when exposed to pressure. Physical examination found no other causes or recurrence.

A diagnostic block was performed on the genital and femoral branches of the right genitofemoral nerve using lidocaine 2%: triamcinolone = 1:1. The patient was placed in a supine position, a linear ultrasound transducer of high frequency (6–13 MHz) was then placed over the femoral artery along its long axis and moved cephalad along the femoral artery until it started to descend at a steep angle towards the inguinal ligament, becoming the external iliac artery. The inguinal canal can be viewed superficial to the vessel as an oval, soft tissue structure. The canal was then scanned medially so that the final ultrasound transducer position was approximately one finger breadth away from the pubic tubercle. Testicular arteries were identified in the spermatic cord as pulsatile structures and confirmed with color Doppler. The vas deferens can also be recognized as a thick, tubular structure. With the in-plane technique, 5 ml of mixture was injected around the spermatic cord. A femoral branch block of the genitofemoral nerve was performed with 5 ml of mixture, injected between the fascia lata and fascia iliaca above the femoral nerve, under ultrasound guidance.



**Figure 1.** (a) genital branch block (b) femoral branch block

The patient was pain-free for one month after the diagnostic block. When the pain came back, we decided to give PRP therapy. Forty cc of blood was drawn from the patient, then double centrifuged, first at 3000 rpm for 3 minutes and second at 3850 rpm for 6 minutes, producing about 10 cc of PRP. After two perineural PRP injections (4-week intervals), the pain in the femoral branch was reduced by 90% and 50% in the genital branch. The patient no longer needs to take any medication and was able to return to normal daily activities.

### Discussion

The genitofemoral nerve originates from the first and second lumbar nerves. It traverses the psoas muscle and divides into genital and femoral branches at a variable distance proximal to the inguinal ligament. In males, the genital branch passes through the internal inguinal ring and travels with the spermatic cord to supply motor fibers to the cremaster muscle and sensory fibers to the scrotum. In females, the genital branch accompanies the round ligament to supply innervation to the labia majora. The femoral branch is located caudad and lateral to the genital branch and travels on the anterior surface of the external iliac artery under the inguinal ligament to supply the skin of the mid-anterior thigh.<sup>7</sup>

Genitofemoral neuralgia is a well-known complication after conventional open inguinal herniorrhaphy. It is thought neuroma formation due to nerve damage plays a role in its etiology. While nerve damage can occur from manipulation, traction, or thermal damage due to cautery during surgery, nerve damage can also occur from inflammation caused by a fibrotic mesh reaction that develops after the surgery or from a granuloma. Most patients describe the neuropathic pain as hypoesthesia, dysesthesia, allodynia, or hyperalgesia at the surgical incision site or in its vicinity. If the injection offers complete but transient relief, surgical removal of the tack or rhizotomy may be indicated. The likelihood of benefit from the tack or staple removal needs to outweigh the possibility of damage to the surgical repair or the nerve during reoperation.<sup>8</sup>

PRP is known for tissue regeneration and widely used in orthopedic cases, but the available evidence shows that PRP is also effective in stimulating nerve regeneration. By releasing biomolecules (namely NGF, BDNF, IGF-1, PDGF, VEGF, HGF, fibrin, fibronectin and vitronectin), PRP activates Schwann cell, polarizes macrophage, promoting regeneration of nerve fibers. PRP plays a role in nerve regeneration through neuroprotection, vascular

regeneration, axon regeneration, inflammation regulation, reduced muscle atrophy, and improvement of neural parameters. PRP also exerts a variety of biological activities including modulating effects on inflammation and angiogenesis that can relieve pain.<sup>5</sup> Lopez et al (2017) reported 45 different cases of peripheral neuropathy, which improved with PRP therapy.<sup>3</sup> Kim et al (2022) conducted an interesting experiment with rabbits to see the regeneration of Recurrent Laryngeal N. between groups that received implants with PRP and implants without PRP. The results showed implants with PRP had better nerve regeneration than those without PRP.<sup>6</sup> PRP therapy for patients with post herniorrhaphy-neuropathy might be the ideal reliable, non-invasive, and low-risk alternative to pharmaceuticals or surgery. Further studies are required to confirm this.

## References

1. Andresen K, Rosenberg J. Management of chronic pain after hernia repair. *J Pain Res.* 2018 Apr 5;11:675-681. doi: 10.2147/JPR.S127820. PMID: 29670394; PMCID: PMC5896652.
2. Gramm-Hanssen A, Öberg S, Rosenberg J. A critical appraisal of the chronic pain rate after inguinal hernia repair. *J Abdom Wall Surg* [Internet]. 2023 Jan; 2:10972. Available from: <https://doi.org/10.3389/jaws.2023.10972>
3. López JC, Cortés H, Ceballos EG, Pizzaro LQ. Platelet-rich plasma in treating peripheral neuropathic pain. Preliminary report. *Rev Soc Esp Dolor* 2018;25(5):263-270.
4. Malessy MJA, de Boer R, Muñoz RI, Eekhof JLA, van Zwet EW, Kliot M, et al. Predictive value of a diagnostic block in focal nerve injury with neuropathic pain when surgery is considered. *PLoS ONE* [Internet]. 2018; 13(9): e0203345. Available from: <https://doi.org/10.1371/journal.pone.0203345>
5. Wang S, Liu X, Wang Y. Evaluation of platelet-rich plasma therapy for peripheral nerve regeneration: A critical review of literature. *Front Bioeng Biotechnol* [Internet]. 2022 March; 10:808248. Available from: <https://doi.org/10.3389/fbioe.2022.808248>
6. Kim JW, Kim JM, Choi ME, Jeon EJ, Park JM, Kim YM, et al. Platelet-rich plasma loaded nerve guidance conduit as implantable biocompatible materials for recurrent laryngeal nerve regeneration. *npj Regen Med* [Internet]. 2022; 7:49. Available from: <https://doi.org/10.1038/s41536-022-00239-2>
7. Peng P, Morrigl B, Seib R. Genitofemoral nerve (inguinal canal) block [Internet]. 2019 Aug 6. Available from: <https://www.asra.com/news-publications/asra-updates/blog-landing/legacy-b-blog-posts/2019/08/06/genitofemoral-nerve-%28inguinal-canal%29-block>
8. Richard H. Rho, Tim J. Lamer, Jack T. Fulmer, Treatment of genitofemoral neuralgia after laparoscopic inguinal herniorrhaphy with fluoroscopically guided tack injection. *Pain Med.* 2001 Sep;2(3):230–233. Available from: <https://doi.org/10.1046/j.1526-4637.2001.01032.x>
9. Dhurat R, Sukesh M. Principles and methods of preparation of platelet-rich plasma: A review and author's perspective. *J Cutan Aesthet Surg.* 2014 Oct-Dec;7(4):189-97. doi: 10.4103/0974-2077.150734. PMID: 25722595; PMCID: PMC4338460.