

## NIMOTUZUMAB IN COMBINATION WITH CHEMORADIATION FOR LOCALLY ADVANCED HEAD AND NECK SQUAMOUS CELL CARCINOMA CANCER PATIENTS: A SINGLE-ARM OBSERVATIONAL STUDY

Sakinah Rahma Sari<sup>1\*</sup>, Andhika Rachman<sup>2</sup>

<sup>1</sup>Faculty of Medicine, Universitas Indonesia, Jakarta, Indonesia,

<sup>2</sup>Hematology and Medical Oncology Division, Department of Internal Medicine, Dr. Cipto Mangunkusumo General Hospital, Universitas Indonesia, Jakarta, Indonesia

eISSN: 2828-4070

Proceedings ICE on IMERI. 2024.

Received: November 30<sup>th</sup>, 2024

Accepted: January 2<sup>nd</sup>, 2025

Published online: January 17<sup>th</sup>, 2025

### Corresponding Author

Name : Sakinah Rahma Sari

Email : sakinahrahmas@alumni.ui.ac.id

### Abstract

**Background:** Head and neck squamous cell carcinoma (HNSCC) incidence is predicted to increase in 2030. Most patients with HNSCC are diagnosed as locally advanced (LA), with a worse prognosis even with combination therapy. Nimotuzumab, a humanized-antibody monoclonal against epidermal growth factor receptor (EGFR), was hypothesized to improve LA-HNSCC patients' survival. This study evaluated the real-world efficacy of adding nimotuzumab to chemoradiation (CRT) in patients with LA-HNSCC survival.

**Methods:** This single-arm retrospective study was conducted in Dr. Cipto Mangunkusumo General Hospital. Patients diagnosed with LA-HNSCC from October 21, 2009, to May 21, 2024 were included. The outcomes assessed were patients' two-year overall survival (OS), two-year progression-free survival (PFS), and treatment toxicities. **Results:** From the total of 30 patients included in the analysis, 93.3% were alive, and 86.7% of patients survived disease progression at the end of the two-year observation. The most common side effects were toxicities against the salivary gland (32.7%), mucous lining (21.2%), and skin (30.8%). **Conclusions:** This single-arm real-world study demonstrated the exceptional efficacy and safety of nimotuzumab in combination with CRT.

### Keywords

Head and neck, squamous cell carcinoma, nimotuzumab, EGFR, survival

## Introduction

Head and neck squamous cell carcinoma (HNSCC) is a type of cancer arising from mucous lining in the head and neck region. Approximately, more than 660.000 new patients worldwide are diagnosed with head and neck cancer annually, contributing to the global health-economic burden.<sup>1</sup> In 2022, about 13.000 new cases were identified in Indonesia and roughly 8.000 deaths were attributable to HNSCC. The overall incidence of HNSCC was predicted to increase to 30% in 2030.<sup>2</sup>

More than 60% of HNSCC patients were initially detected as locally advanced (LA).<sup>3</sup> LA-HNSCC encompasses patients with T3-4 or N1-3 according to The American Joint Committee on Cancer (AJCC) 8<sup>th</sup> edition staging system. This group of patients has a worse prognosis and a higher risk of recurrence than the earlier stages.<sup>4</sup> Generally, a combination of surgery, radiotherapy (RT), and systemic therapy are required in LA-HNSCC management. The standard treatment options are surgery, along with adjuvant chemoradiation or primary concomitant chemoradiation.<sup>5</sup> Despite being preferred for better functional preservation, concurrent platinum-based chemotherapy with RT offer only less than 50% of five-year survival benefit.<sup>6</sup> Thus, there is a pressing necessity for novel therapeutic approaches in LA-HNSCC.

Epidermal growth factor receptor (EGFR), a member of the tyrosine kinase receptor family, is overexpressed in more than 90% of HNSCC patients. Overexpression of EGFR is associated with poor prognosis related to its role in tumor proliferation, angiogenesis, and invasion.<sup>7-9</sup> Hence, EGFR inhibitors can be a plausible therapeutic agent for LA-HNSCC.

Nimotuzumab, a humanized monoclonal antibody, has optimal affinity against EGFR's extracellular domain.<sup>10</sup> Several studies revealed combining nimotuzumab with concurrent chemoradiation will increase clinical response with lower toxicity in LA-HNSCC patients.<sup>11,12</sup> BEST trial, a phase IIb randomized study involving 76 patients in India, showed that combining nimotuzumab with chemoradiation (CRT) provided better five-year overall survival than CRT or RT alone (57% vs 26% vs 39%).<sup>13</sup> A randomized phase III trial by Patil et al revealed that adding nimotuzumab to patients' chemoradiation significantly improved patients' 10-year OS by 11% (33.5% vs 22.5%,  $p=0.044$ ).<sup>14</sup> Beforehand, there was no data recorded regarding nimotuzumab's effects on LA-HNSCC patients in Indonesia. This single-center observational study aimed to evaluate the efficacy and safety of adding nimotuzumab to CRT in patients with LA-HNSCC.

## **Materials and Methods**

### **Data source**

This single-center study was conducted in Dr. Cipto Mangunkusumo General Hospital, involving the Department of Internal Medicine, the Department of Radiation Oncology, and the Department of Ear, Nose, and Throat (ENT). Both printed and electronic medical records from October 21, 2009, to May 21, 2024, were utilized as data sources.

### **Patient selection**

Patients with histologically confirmed LA-HNSCC from October 21, 2009, to May 21, 2022, in dr.Cipto Mangunkusumo General Hospital were observed retrospectively. Patients who previously underwent CRT were excluded. Patients in the intervention group received intravenous (IV) nimotuzumab 200 mg weekly for 6 weeks, IV platinum-based chemotherapy for 6 cycles, and intensity-modulated radiotherapy (IMRT) with 60-70 Gy for 30-35 cycles.

### **Study endpoints**

The primary outcomes evaluated in this observational study were patients' survival in the form of two-year real-world overall survival (rwOS) and two-year real-world progression-free survival (rwPFS). Overall survival was defined as patients' survival from any cause of death during the observatory time after treatment initiation. Meanwhile, patients' survival before disease progression including tumor growth and spread was defined as progression-free survival. Patients with no recorded death, disease progression, or loss of follow-up were censored. The secondary outcome assessed in this study was the adverse effects of patients' treatment.

### **Data analysis**

The data analysis was performed using SPSS version 27.0 (IBM Corp., Armonk, NY). The primary outcomes were evaluated using Kaplan-Meier analysis. Patient characteristics and treatment toxicities were assessed and reported as categorical and continuous variables.

## **Results**

### **Baseline characteristics**

A total of 30 patients receiving a combination of nimotuzumab and chemoradiation were included in the final analysis. More than half of the patients were male (60.0%). Most patients were diagnosed as stage IVA LA-HNSCC (53.3%). The majority of cases originated from larynx (50.0%), followed by tongue (20.0%). Patients' pre-treatment functional status was evaluated and collected. Most patients were assessed as ECOG 0 (93.3%). Further information regarding patients' baseline characteristics was tabulated in Table 1.

**Table 1.** Baseline characteristics

	Nimotuzumab + CRT (30)
Age	58.23 ± 12.89
Gender	
Male	18 (60.0%)
Female	12 (40.0%)
Clinical Staging	
Stage III	12 (40.0%)
Stage IVA	16 (53.3%)
Stage IVB	2 (6.7%)
Comorbidities	
Yes	7 (23.3%)
No	23 (76.7%)
ECOG	
0	28 (93.3%)
1	2 (6.7%)
2	0 (0.0%)
Tumor Site	
Larynx	15 (50.0%)
Tongue	6 (20.0%)
Oropharynx	2 (6.7%)
Hypopharynx	2 (6.7%)
Others	5 (16.7%)
Geographical Origin	
Java	26 (86.7%)
Sumatera	3 (10.0%)
Kalimantan	0 (0.0%)

Sulawesi	1 (3.3%)
----------	----------

### Survival analysis

The two-year rwOS and the two-year rwPFS were presented in the form of Kaplan-Meier survival curves (Fig. 1 and Fig.2). The two-year rwOS of LA-HNSCC patients receiving a combination of nimotuzumab and CRT in Dr. Cipto Mangunkusumo General Hospital was 93.3%. The mean survival time was 22.95 (95% CI [21.49-24.40]) months and the median survival time was not reached at the end of our observation. Aside from the superb two-year rwOS, nimotuzumab also offered an exceptional 2-year PFS benefit (86.7%). The mean PFS time of LA-HNSCC patients in this study was 22.19 (95% CI [20.36-24.02]) months.

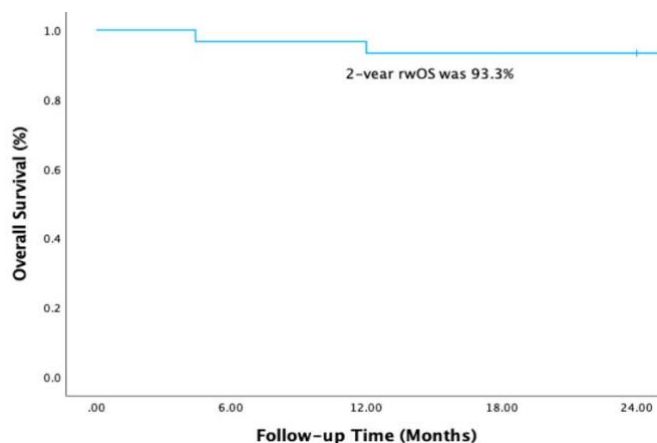


Figure 1. Kaplan-Meier survival curve for two-year rwOS

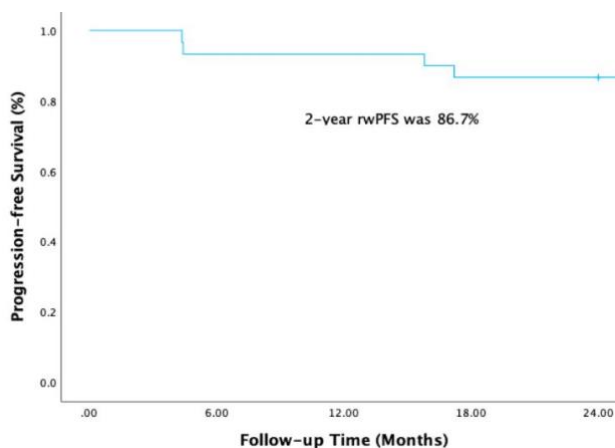


Figure 2. Kaplan-Meier survival curve for two-year rwPFS

**Treatment toxicities**

The most common side effects were toxicity against the salivary gland (32.7%), mucous lining (21.2%), and skin (30.8%). The majority of adverse effects were grade I and tolerable. More information about treatments' toxicity were presented in Table 2.

**Table 2.** Treatment toxicities

	Nimotuzumab (30)
Skin	
0	24 (80.0%)
1	6 (20.0%)
2	0 (0.0%)
3	0 (0.0%)
Mucosa	
0	26 (86.7%)
1	4 (13.3%)
2	0 (0.0%)
3	0 (0.0%)
Eye	
0	29 (96.7%)
1	1 (3.3%)
2	0 (0.0%)
3	0 (0.0%)
Ear	
0	30 (100.0%)
1	0 (0.0%)
2	0 (0.0%)
3	0 (0.0%)
Salivary gland	
0	23 (76.7%)
1	7 (23.3%)
2	0 (0.0%)
3	0 (0.0%)

Pharynx	
0	25 (83.3%)
1	5 (16.7%)
2	0 (0.0%)
3	0 (0.0%)
Larynx	
0	29 (96.7%)
1	1 (3.3%)
2	0 (0.0%)
3	0 (0.0%)
CNS	
0	30 (100.0%)
1	0 (0.0%)
2	0 (0.0%)
3	0 (0.0%)
Blood	
0	29 (96.7%)
1	1 (3.3%)
2	0 (0.0%)
3	0 (0.0%)

## Discussion

Nimotuzumab improves the efficacy of chemoradiation potentially through its involvement in reducing tumor cell proliferation, angiogenesis, and invasion by blocking EGFR signalling pathway. Aside from that, EGFR overexpression was hypothetically expected to cause resistance towards radiotherapy and chemotherapy. Oxidative stress following radiation could trigger Akt signalling mediated by EGFR resulting in tumor survival. Therefore, nimotuzumab as a monoclonal antibody against EGFR could enhance tumor killing by limiting free radical-induced Akt mediated cell survival and increasing sensitivity towards chemotherapy.<sup>15,16</sup>

Previous study by Bahl et al. stated the one-year OS was 90% and 1.5-year OS was 71% in patients receiving nimotuzumab in combination with CRT.<sup>17</sup> BEST trial, a randomized study from India, also identified nimotuzumab's benefit in combination with either CRT or RT towards patients' five-year OS (57% vs 26% vs 39%).<sup>13</sup> A phase III randomized trial involving 534 patients by Patil et al. revealed an improvement of the 10-year OS in patients

receiving the combination of nimotuzumab and CRT compared to CRT alone (33.5% vs 22.5%, HR 0.841; 95% CI [0.66-0.99],  $p=0.04$ ).<sup>14</sup> A meta-analysis with 126 RCT included by Wang et al. comparing various treatment regimens for patients with LA-HNSCC showed that the combination of nimotuzumab with cisplatin and RT may be the most promising treatment option for LA-HNSCC and resulted in the best OS in comparison with other regimens.<sup>18</sup> Our study, consistent with previous studies, revealed that combining nimotuzumab and CRT resulted in similar two-year rwOS in LA-HNSCC patients (93.3%).<sup>13,14,18</sup>

As mentioned in the study by Pontes et al, the prognosis of recurrent or metastatic (r/m) HNSCC was generally poor. The relative five-year OS in r/m HNSCC was less than 50%.<sup>19</sup> Moreover, this group of patients tend to require more resources but with lower quality of life. Hence, patients' first-line regimen was crucial to minimize the risk of disease progression. A previous trial by Patil et al indicated a more pronounced 2-year PFS benefit in the nimotuzumab and CRT arm compared to the CRT arm (61.8% vs 50.1%, HR 0.69; 95% CI [0.53-0.89],  $p=0.004$ ). The higher PFS in patients receiving the combination of nimotuzumab and CRT may suggest that this combination provides better locoregional control than CRT alone. According to a randomized trial by Patil et al., the 2-year locoregional control (LRC) was significantly better in the combination of nimotuzumab and CRT than in CRT alone (67.5% vs 57.6%, HR 0.67; 95% CI [0.50-0.89],  $p=0.005$ ).<sup>20</sup> This study also revealed that adding nimotuzumab to patients' chemoradiation resulted in two-year rwPFS as high as 86.7%. Therefore, its utilization as patients' first line regimen should be considered.

In comparison with other anti-EGFR agents, nimotuzumab provided more tolerable safety profile. High prevalence of skin toxicity (60-80%) was reported with other EGFR agents.<sup>21</sup> Meanwhile in this study, grade I skin toxicity occurred in only 20% of patients receiving nimotuzumab. Compared to cetuximab, nimotuzumab demonstrated less side effects, which is attributed to a more selective binding. Unlike other EGFR blockers, nimotuzumab requires bivalent binding for a stable attachment to EGFR surface. In cells with lower expression of EGFR, nimotuzumab tends to bind transiently. This reduced binding of nimotuzumab to cells with lower expression of EGFR could explain the lesser toxicity found in nimotuzumab compared to other anti-EGFR agents.<sup>22</sup> This study recognized that adding nimotuzumab to patients' chemoradiation did not increase treatment's adverse events while being more efficacious.

### **Limitation**

First of all, the retrospective design of this single-center study may limit result generalizability and reliability due to potential sample size and selection biases. Secondly, the single-arm study design prevented direct comparison with standard concurrent chemoradiation, limiting benchmarking of treatment efficacy in the same clinical setting.



Third, the median survival time was not reached within the study observation period. Longer follow-up time would be necessary for data collection and further analysis.

## Conclusions

In summary, this retrospective observational study demonstrated the real-world survival efficacy and safety of nimotuzumab in combination with CRT, with outcomes consistent with those of pivotal clinical trials, for treating patients with LA-HNSCC

## Conflict of Interest

We declare no conflict of interest during the conduction of this study.

## Acknowledgments

This article was presented at the 9<sup>th</sup> International Conference and Exhibition on Indonesian Medical Education and Research Institute (9<sup>th</sup> ICE on IMERI) 2024, Faculty of Medicine, Universitas Indonesia. We are grateful for the outstanding assistance provided by the committee of The 9<sup>th</sup> ICE on IMERI 2024 throughout the preparation of the manuscript and the peer-review process.

## References

1. Sung H, Ferlay J, Siegel R L, Laversanne M, Soerjomataram I, Jemal A, et al. Global Cancer Statistics 2020: GLOBOCAN Estimates of Incidence and Mortality Worldwide for 36 Cancers in 185 Countries. *CA Cancer J Clin* 2021; 71: 209-249.
2. Ferlay J, Ervik M, Lam F, Laversanne M, Colombet M, Mery L, Piñeros M, Znaor A, Soerjomataram I, Bray F. 2024. Global Cancer Observatory: Cancer Today. Lyon, France: International Agency for Research on Cancer. Available from: <https://gco.iarc.who.int/today>, accessed [25 July 2024].
3. Perri F, Ionna F, Muto P, Marzo MD, Caponigro F, Longo F, et al. Genetics and management of locally advanced carcinomas of the head and neck: role of altered fractionation radiotherapy. *Future Sci OA*. 2018;5(1):FSO347. Published 2018 Oct 26. doi:10.4155/fsoa-2018-0058.

4. Chow LQM. Head and neck cancer. *N Engl J Med.* 2020;382:60–72. doi:10.1056/NEJMra1715715.
5. Machiels JP, Leemans CR, Golusinski W, Grau C, Licitra L, Gregoire V. Squamous cell carcinoma of the oral cavity, larynx, oropharynx and hypopharynx: EHNS–ESMO–ESTRO Clinical Practice Guidelines for diagnosis, treatment and follow-up. *Annals of oncology.* 2020;31(11):1462-75. doi: 10.1016/j.annonc.2020.07.011.
6. Ang MK, Montoya JE, Tharavichitkul E, Lim C, Tan T, Wang LY, et al. Phase II study of nimotuzumab (TheraCim-hR3) concurrent with cisplatin/radiotherapy in patients with locally advanced head and neck squamous cell carcinoma. *Head & Neck.* 2021;43:1641–51. doi: 10.1002/hed.26635.
7. Kalyankrishna S, Grandis JR. Epidermal growth factor receptor biology in head and neck cancer. *J Clin Oncol.* 2006 Jun 10;24(17):2666-72. doi: 10.1200/JCO.2005.04.8306. PMID: 16763281.
8. Grandis JR, Tweardy DJ. Elevated levels of transforming growth factor alpha and epidermal growth factor receptor messenger RNA are early markers of carcinogenesis in head and neck cancer. *Cancer Res* 1993;53:3579-84.
9. Xu MJ, Johnson DE, Grandis JR. EGFR-targeted therapies in the post-genomic era. *Cancer Metastasis Rev* 2017;36:463-73. 10.1007/s10555-017-9687-8.
10. Crombet-Ramos T, Rak J, Pérez R, Vilorio-Petit A. Antiproliferative, antiangiogenic and proapoptotic activity of h-R3: A humanized anti-EGFR antibody. *Int J Cancer.* 2002;101(6):567-575. doi:10.1002/ijc.10647.
11. Subramanian S, Sridharan N, Balasundaram V, Chaudhari S. Efficacy and safety of nimotuzumab in unresectable, recurrent, and/or metastatic squamous cell carcinoma of the head and neck: A hospital-based retrospective evidence. *South Asian J Cancer.* 2018;7(3):188-192. doi:10.4103/sajc.sajc\_87\_18.
12. Bhatnagar AR, Singh DP. A comparative study of a monoclonal antibody against EGFR (nimotuzumab) used in combination with chemoradiation versus chemoradiation alone in the treatment of locally advanced inoperable squamous cell carcinoma of the head and neck. *J Clin Oncol.* 2012;30(Suppl 30):51.
13. Reddy BK, Lokesh V, Vidyasagar MS, Shenoy K, Babu KG, Shenoy A, et al. Nimotuzumab provides survival benefit to patients with inoperable advanced squamous cell carcinoma of the head and neck: A randomized, open-label, phase IIb, 5-year study in Indian patients. *Oral Oncol.* 2014;50:498–505.

14. Patil VM. 2024. Long term results of a randomized phase III nimotuzumab in combination with concurrent radiotherapy and cisplatin versus radiotherapy and cisplatin alone, in locally advanced squamous cell carcinoma of the head and neck. Presented in ASCO annual meeting 2024. Chicago.
15. Wang X, McCullough KD, Franke TF, Holbrook NJ. Epidermal growth factor receptor-dependent akt activation by oxidative stress enhances cell survival. *The journal of biological chemistry*. 2000;275: 14624-31. doi:10.1074/jbc.275.19.14624.
16. Ngan RK, Yiu HH, Lau WH, Yau S, Cheung FY, Chan TM, et al. Combination gemcitabine and cisplatin chemotherapy for metastatic or recurrent nasopharyngeal carcinoma: report of a phase ii study. *Annals of oncology*. 2002;13:1252-8. doi:10.1093/annonc/mdf200.
17. Bahl A, Singh K, Choudhary P, Anand AK, Chaoudhoory AR, Chaturvedi H, et al. Nimotuzumab with Concurrent Chemoradiation in Inoperable Locally Advanced Squamous Cell Carcinoma of Head and Neck: An Indian Experience. *Journal of cancer therapy*. 2018;9:89-100. doi:10.4236/jct.2018.91010.
18. Wang H, Zheng Z, Zhang Y, Bian C, Bao J, Xin Y and Jiang X. Locally advanced head and neck squamous cell carcinoma treatment efficacy and safety: a systematic review and network meta-analysis. *Front. Pharmacol*. 2023;14:1269863. doi: 10.3389/fphar.2023.1269863.
19. Pontes F, Garcia AR, Domingues I, Sousa MJ, Felix R, Amorim C, et al. Survival predictors and outcomes of patients with recurrent and/or metastatic head and neck cancer treated with chemotherapy plus cetuximab as first-line therapy: A real-world retrospective study. *Cancer treatment and research communications*. 2021;27:100375.
20. Patil VM, Noronha V, Joshi A, Agarwal J, Gosh-Laskar S, Budrukkar A, et al. A Randomized Phase 3 Trial Comparing Nimotuzumab Plus Cisplatin Chemoradiotherapy Versus Cisplatin Chemoradiotherapy Alone in Locally Advanced Head and Neck Cancer. *Cancer*. 2019;125(18):3184-97. doi: 10.1002/cncr.32179.
21. Agero AL, Dusza SW, Benvenuto-Andrade C, Busam, KJ, Myskowski P, Halpern AC. Dermatologic side effects associated with the epidermal growth factor receptor inhibitors. *Journal of the american academy of dermatology*. 2006;55:657-70. doi:10.1016/j.jaad.2005.10.010.
22. Mazorra Z, Chao L, Lavastida A, et al. Nimotuzumab: beyond the EGFR signaling cascade inhibition. *J seminoncol*. 2018;45:18-26. doi: 10.1053/j.seminoncol.2018.04.008.

